

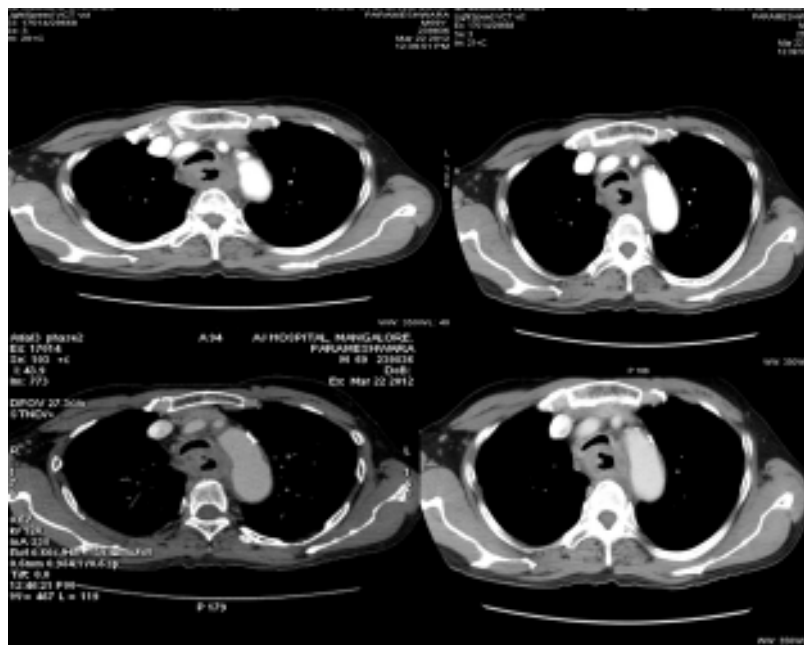
## Self assessment Quiz

### Vishnu Sharma M.

Pulmonary Medicine, Professor and Head, A.J. Institute of Medical Science,

Correspondences: Vishnu Sharma M  
Pulmonary Medicine, Professor and Head,  
A.J. Institute of Medical Science, Mangalore, Karnataka

1. This is the CT thorax image of a patient who presented with chronic cough and weight loss. He also complained of dysphagia. What is the most likely diagnosis ?



2. What is the next diagnostic investigation ?
  - Barium swallow
  - Barium meal follow through
  - Upper GI scopy
  - CT guided true cut biopsy
  - Bronchoscopy
3. Which one of the following is most common pulmonary complication of esophageal carcinoma
  - Secondary in the Lungs
  - Malignant pleural effusion
  - Aspiration pneumonia
  - Tracheal compression
  - Tracheo esophageal fistula
4. Which of the following is the most common cause for acquired Tracheo esophageal fistula ?
  - Bronchogenic carcinoma
  - Carcinoma of esophagus
  - Trauma
  - Prolonged intubation
  - Infections