

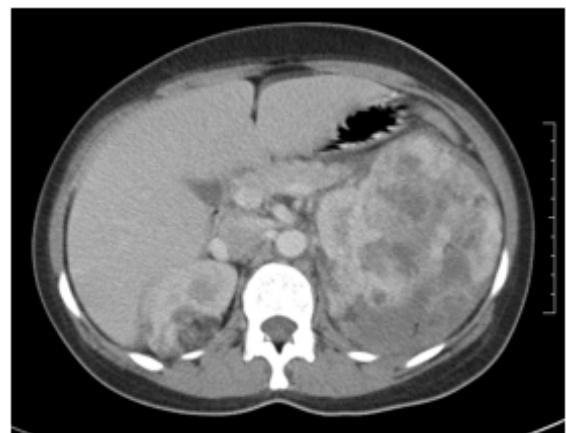
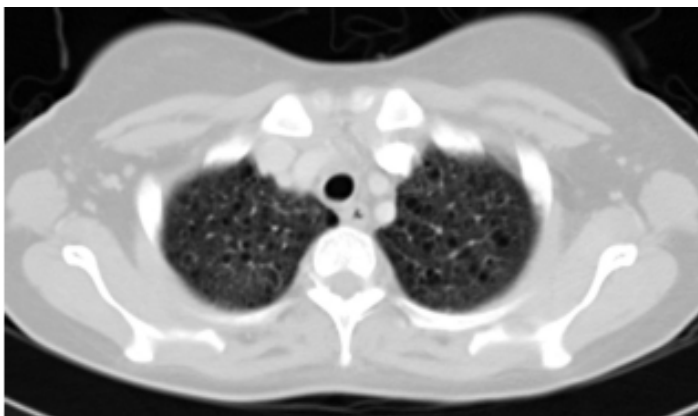
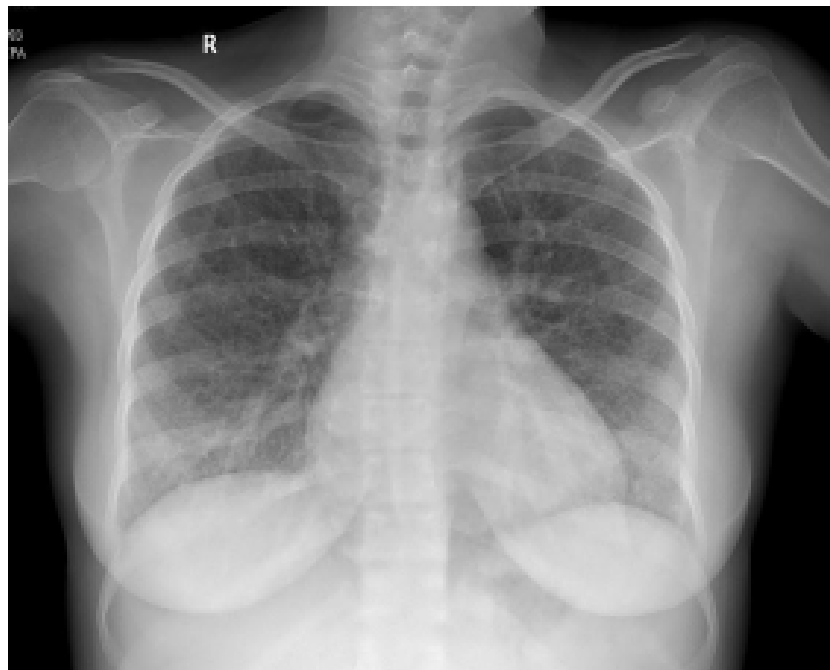Radiology Quiz

Rajesh V, Asmita Mehta

Associate Professors, Department of Pulmonary Medicine, AIMS, Kochi

Correspondences: Rajesh V
Email rajeshdhanya@rediffmail.com

A 26 year old lady with subnormal mental function from birth presented with acute intra abdominal bleeding. She never complained of any respiratory symptoms. A routine chest radiograph obtained prior to surgical exploration was abnormal and finger oximetry revealed SpO₂ of 92% on room air. An emergency computerised tomographic evaluation of the thorax and abdomen was performed, the representative images of which are exhibited along with the chest roentgenogram. What is the diagnosis?



Answer in Page : 115