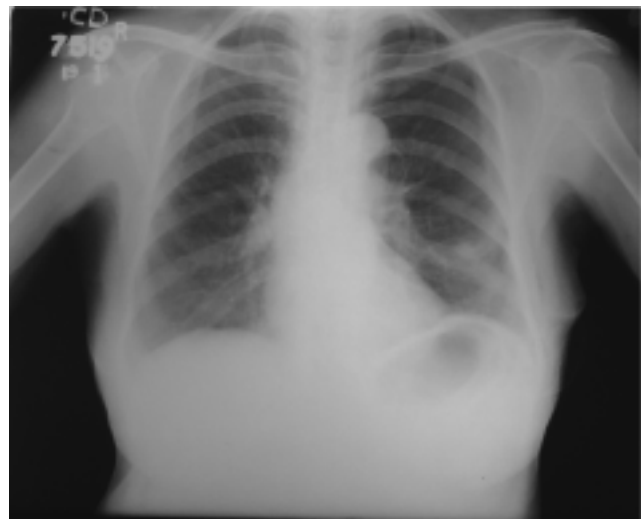
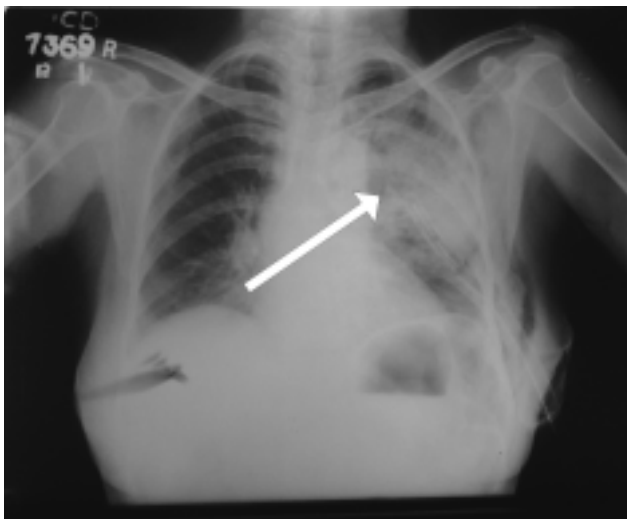
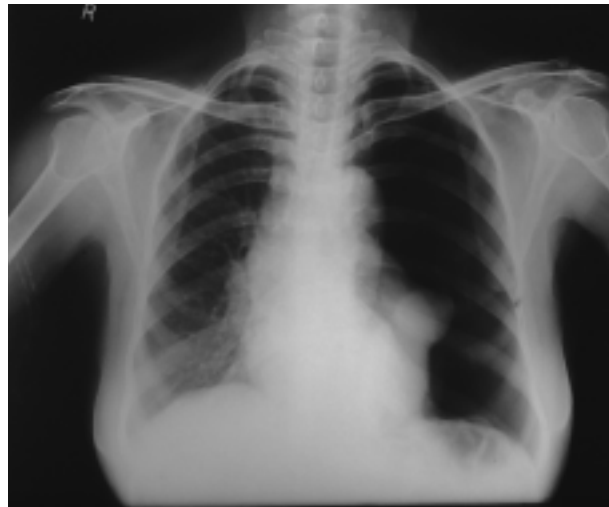


Radiology Quiz

***Sunny George, *Anandan.P.T, **P.T.James**

*Associate Professor , * * Professor
Dept.of.Pulmonary Medicine, Govt.Medical College, Kozhikode.

Correspondences: Dr. Sunny George
Associate Professor, Department of Pulmonary Medicine,
Government Medical College, Kozhikode. sunsunal@gmail.com



The most likely reason for the non homogenous opacity seen on the left side lung field(bold white arrow) in the second Chest X-ray in an elderly female admitted with left sided acute chest pain which got cleared (3rd Chest X-ray) with supportive management and high flow oxygen.