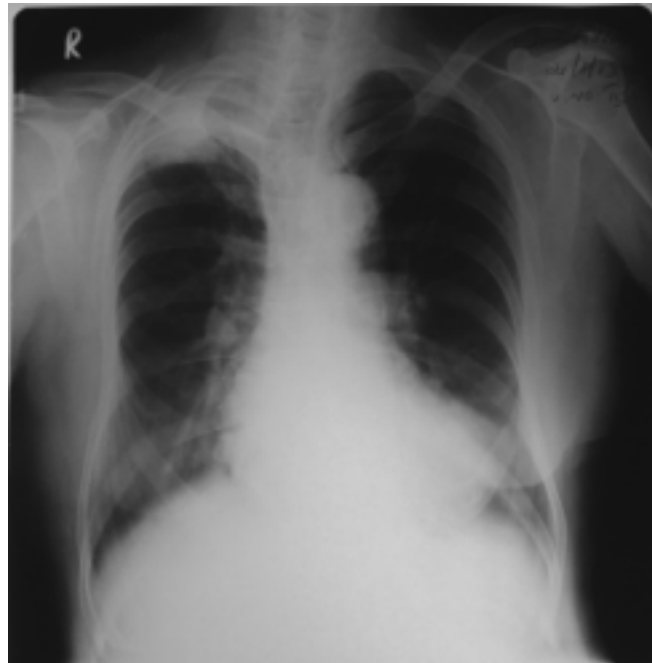


Radiology Quiz

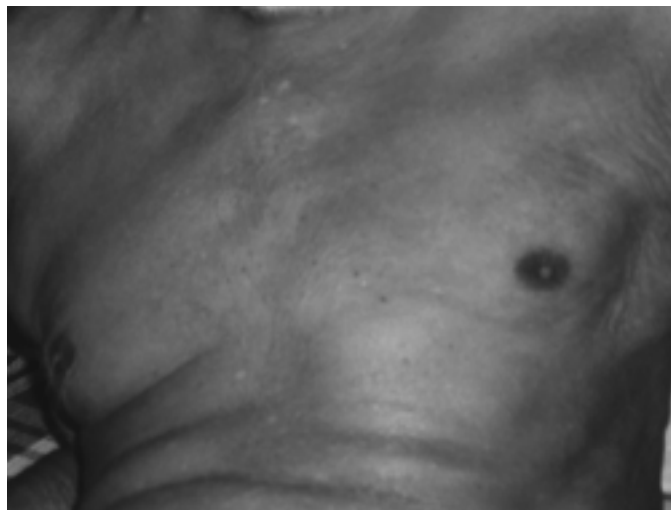
Kiran Vishnu Narayan*, **Sunny George****, **Anandan P T****, **James P.T. *****

*Assistant Professor, **Associate Professor, *** Professor
Dept.of.Pulmonary Medicine, Govt.Medical College, Kozhikode.

Correspondences: Dr. Sunny George,
Associate Professor, Department of Pulmonary Medicine,
Government Medical College, Kozhikode. sunsuna1@gmail.com



Chest X-ray PA view



This elderly male was diagnosed to have right upper lobe mass lesion which was proved to be carcinoma lung. His left lower zone showed an abnormal shadow not silhouetting with the cardiac border. He did not have gynaecomastia. Possible Diagnosis?

Answer in Page : 36