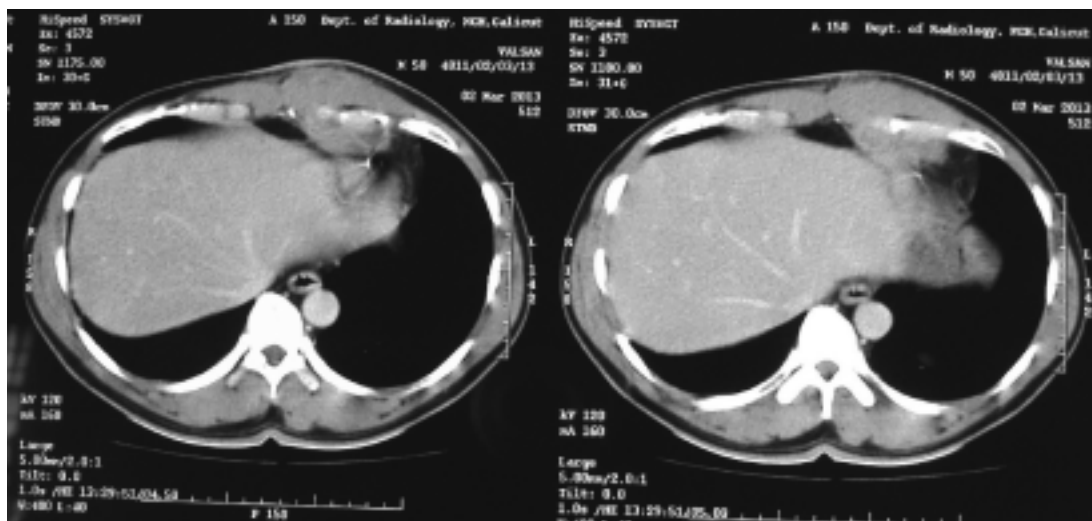
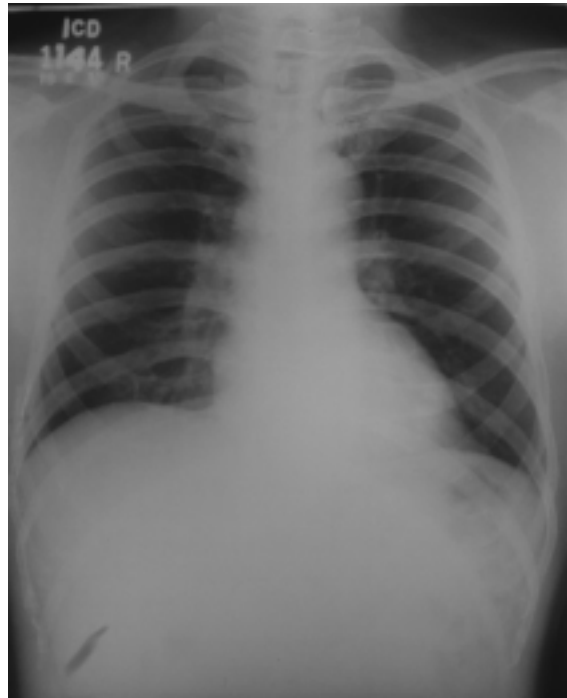

## Radiology Quiz

Sunny George\*, Anandan P.T\*, James P.T \*\*

\*Associate Professor, \*\* Professor  
Dept.of.Pulmonary Medicine, Govt.Medical College, Kozhikode.

Correspondences: Dr. Sunny George,  
Associate Professor, Department of Pulmonary Medicine,  
Government Medical College, Kozhikode. sunsuna1@gmail.com



50 yr old male with Diabetes, presenting with this chest X-ray &  
CT chest was started on CAT-I DOTS. Diagnosis?

Answer in Page : 109